Knupp A, Chang L. Amiodarone-Induced Diffuse Alveolar Hemorrhage in a Patient with Interstitial Lung Disease and Recent Coronary Artery Bypass Grafting: Diagnosis and Treatment of a Rare Complication. *ObsInsPulmCrit*. Published online November 24, 2026. doi:10.2458/001c.172323

Pulmonary

Amiodarone-Induced Diffuse Alveolar Hemorrhage in a Patient with Interstitial Lung Disease and Recent Coronary Artery Bypass Grafting: Diagnosis and Treatment of a Rare Complication

Alec Knupp, DO[1], Lydia Chang, MD[2]

[1] Internal Medicine, Mountain Area Health Education Center, [2] Pulmonary and Critical Care, Mission Hospital

Keywords: diffuse alveolar hemorrhage, DAH, amiodarone, amiodarone pulmonary toxicity, diffuse lung disease, CABG, atrial fibrillation

https://doi.org/10.2458/001c.172323

Observations and Insights in Pulmonary and Critical Care

ABSTRACT

Amiodarone is a class III antiarrhythmic medication widely used to treat atrial fibrillation and cardiac arrest. Despite its efficacy, serious adverse effects can occur, including the rare complication of diffuse alveolar hemorrhage (DAH). We report a 78-year-old man with non-idiopathic pulmonary fibrosis, a subtype of interstitial lung disease (ILD), receiving amiodarone for atrial fibrillation following coronary artery bypass grafting (CABG) who presented with three days of worsening dyspnea, eventually requiring mechanical ventilation. DAH was diagnosed by chest computed tomography and bronchoalveolar lavage. We discontinued amiodarone, and the patient received five days of intravenous methylprednisolone followed by a high-dose oral prednisone taper, resulting in marked improvement, successful extubation, and eventual hospital discharge. This patient highlights a rare but potentially life-threatening complication of a commonly prescribed medication and underscores the importance of recognizing amiodarone-induced DAH in patients presenting with acute respiratory failure. Whether patients with pre-existing lung disease or recent major cardiothoracic surgery are at risk for amiodarone-induced DAH warrants further study.

INTRODUCTION

Amiodarone is one of the most commonly used anti-arrhythmic medications in the United States. Its efficacy is well established, but side effects including hepatic, thyroid, and pulmonary toxicity are common.[1-3] Amiodarone-induced pulmonary toxicity occurs in an estimated 1–2% of users, most commonly manifesting as a transient pneumonitis with a per-case fatality rate approaching 10%. Associated conditions commonly include pleural effusion(s) and airway edema.[4-6] A subset of these patients that develop severe toxicity will progress to acute respiratory distress syndrome (ARDS), a condition carrying up to a 50% fatality rate.[6] Amongst amiodarone-induced lung injury, DAH represents an exceptionally rare but disproportionately lethal subset. Although patients with underlying ILD are at risk for pulmonary complications after cardiac surgery, only a few individual case reports describe a link between pre-existing lung disease or cardiothoracic surgery and amiodarone-induced DAH. Atrial fibrillation is a very common complication following CABG, and amiodarone is frequently used in these patients with pre-existing lung disease.[2,4] Whether pre-existing lung disease, recent cardiothoracic surgery, or both in a synergistic fashion confer a clinically significant increased risk for amiodarone-induced DAH remains an important unanswered question.

CASE PRESENTATION

A 78-year-old man with pulmonary fibrosis diagnosed five years earlier and recent CABG complicated by persistent postoperative atrial fibrillation presented with three days of worsening cough, dyspnea, and scant hemoptysis. Amiodarone 400 mg and warfarin daily had been started approximately 2 months prior. On admission, he was hypoxemic with an oxygen saturation of 78% on 2 L/min nasal cannula. Laboratory evaluation revealed a hemoglobin of 7.2 g/dL and a supratherapeutic international normalized ratio (INR) of 4.1.

Chest radiography, demonstrated in Figure 1b, revealed new bilateral patchy opacities compared with imaging obtained two months earlier (1-A).

We discontinued warfarin, administered 10 mg IV vitamin K, and transfused two units of packed red blood cells (pRBCs) and prothrombin complex concentrate. Computed tomography (CT) of the abdomen and pelvis with IV contrast ruled out intra-abdominal or retroperitoneal hemorrhage. Chest CT with IV contrast, shown in Figure 2b and compared with imaging from two months earlier (2-A), revealed new diffuse ground-glass opacification with unchanged underlying fibrosis. Given these findings, we discontinued amiodarone. Infectious workup, including a respiratory viral panel, was negative. Serologic studies for antinuclear antibody (ANA), anti-neutrophil cytoplasmic antibodies (ANCA), and anti-glomerular basement membrane (anti-GBM) were negative. Over the first 48 hours of admission, his oxygen requirement increased from 2 L/min to 50 L/min via high-flow NC. Hemoglobin remained unstable, ranging from 6.0 to 7.2 g/dL despite transfusion of eight units of pRBCs. Consent was obtained for elective intubation which was performed immediately prior to diagnostic bronchoscopy with bronchoalveolar lavage (BAL).

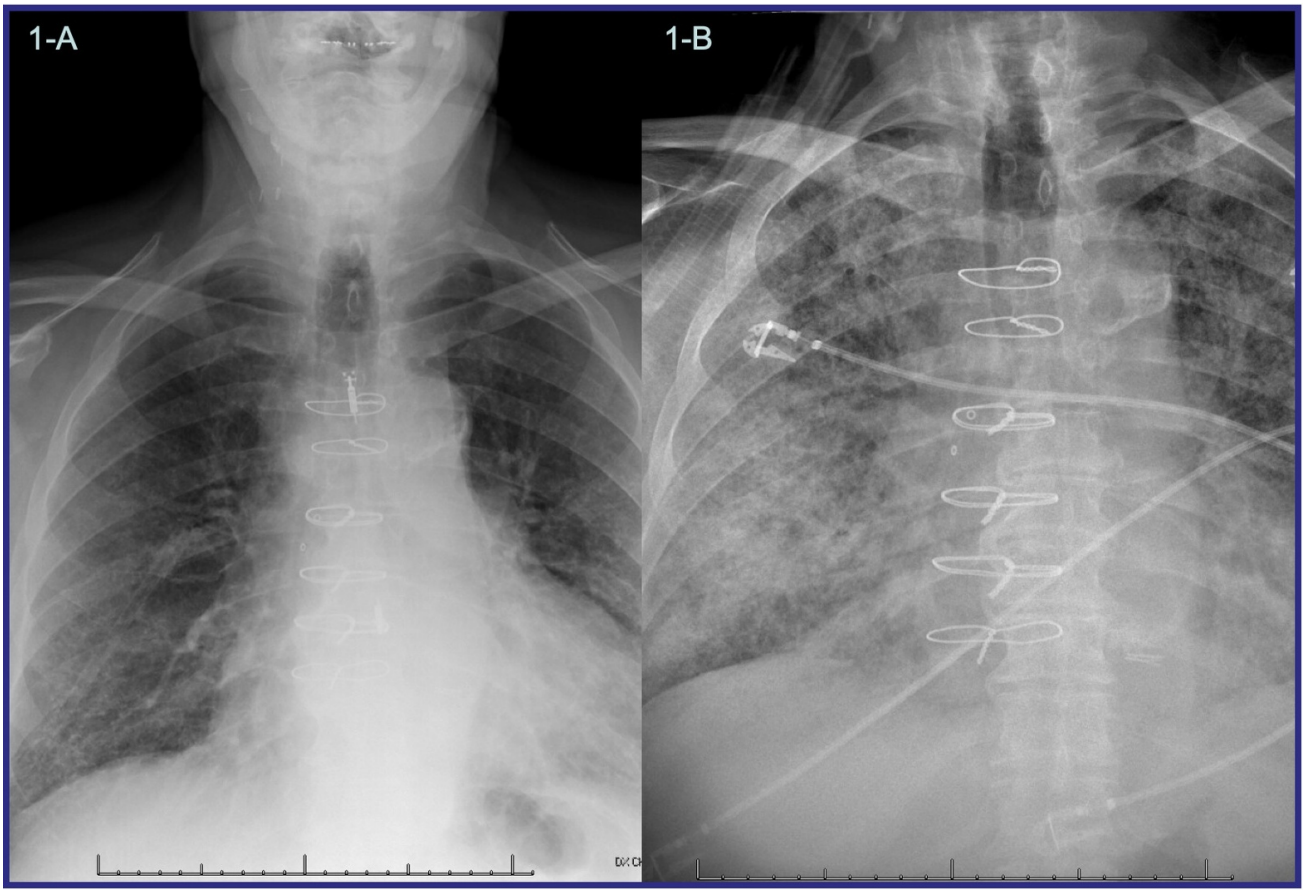

Figure 1. Radiographic imaging of the patient's chest from two months prior to presentation (1a), compared with initial imaging on hospital admission (1b).

During the lavage phase, the four aliquots of bronchoalveolar-rinsed saline returned progressively bloodier. DAH was preliminarily diagnosed, and he received 250 mg IV methylprednisolone. On inpatient day three, BAL gram stain and cultures were negative. Cytology showed red blood cells 23,000 cells/µL, 70% lymphocytes and 25% neutrophils.

Seventy-two hours later, on inpatient day six, his hemoglobin had stabilized and, after passing a spontaneous breathing trial, the patient was extubated without incident. He received IV methylprednisolone for a total of five days before transitioning to an oral prednisone taper. One year after discharge, he has not needed to increase his home oxygen regimen and has not been hospitalized.

DISCUSSION

Amiodarone-induced DAH is a diagnosis of exclusion, established in this patient through radiographic findings and BAL demonstrating progressively hemorrhagic returns after infectious, autoimmune, and alternative hemorrhagic etiologies were excluded.[5,7,8] Key clinical features included falling hemoglobin refractory to transfusion, scant hemoptysis, and new bilateral ground-glass opacities (Figure 2b) with rapidly progressive hypoxemia. Hemoptysis may be absent in up to half of DAH cases, making unexplained anemia with new infiltrates a clue to the diagnosis.[2,9] Amiodarone is a potent inhibitor of the metabolic clearance of both the S- and R-enantiomers of warfarin, potentiating warfarin's anticoagulant effect.[10] This likely explains our patient's supratherapeutic INR on presentation, and added another layer of complexity to the management of severe DAH with refractory hypoxemia. Failure to stabilize with successful anticoagulant reversal alone, with improvement only after IV corticosteroids, further supports amiodarone as the primary driver. The BAL lymphocytosis could also suggest a drug reaction, as DAH is classically predominantly neutrophilic. The patient's extubation within 72 hours and discharge at baseline contrast sharply with the reported fatality rate exceeding 50%, likely reflecting early recognition and aggressive intervention.[4] Prompt discontinuation of amiodarone and high-dose IV corticosteroids remain the cornerstone of management.[2,7] A prior case of clinically diagnosed DAH attributed to the use of amiodarone for CABG-provoked atrial fibrillation emphasized that prior lung disease and the stress of cardiothoracic surgery seemed to heighten the risk of pulmonary toxicity.[11] In 2011, the Society of Thoracic Surgeons (STS) included pre-existing lung disease and DAH from amiodarone toxicity as established risk factors in its guidelines.[12] Given amiodarone's widespread use across specialties, maintaining a low threshold for DAH evaluation in at-risk patients is essential. The exact mechanisms by which pre-existing ILD and recent CABG contribute to amiodarone-induced DAH remain unknown. This case aims to increase aware-

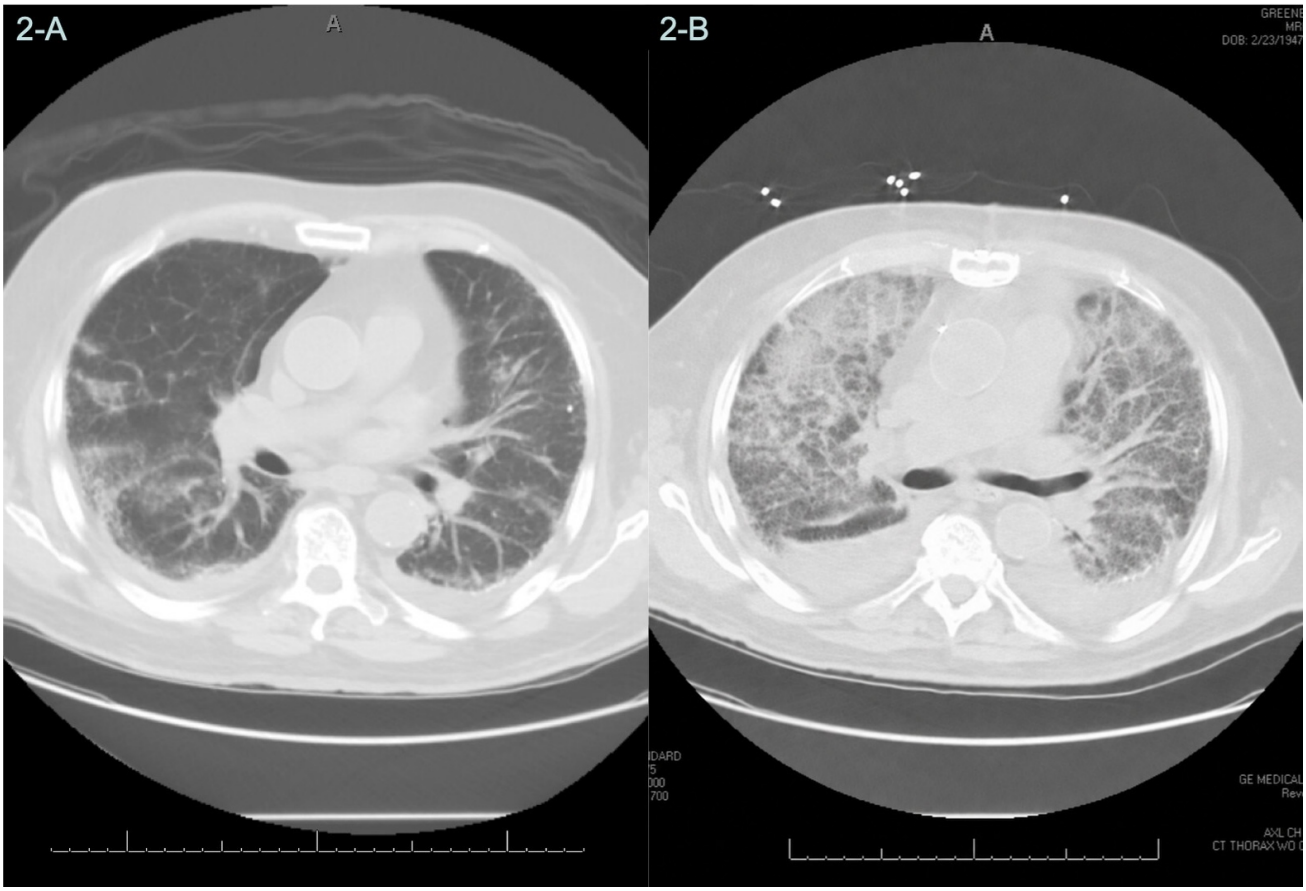

Figure 2. Chest Computed Tomography (CT) w/ IV contrast of the patient from two months prior (2a) compared with day of admission (2b). New appearance of bilateral ground glass opacities (GGOs) along with a degree of crazy paving was noted.

ness that amiodarone-induced DAH is a treatable complication of therapy, and that patients with pre-existing lung disease, anticoagulation for atrial fibrillation, or recent CABG cardiothoracic surgery are an at-risk population.[12]

Published: November 24, 2026 MST.

This is an open-access article distributed under the terms of the Creative Commons Attribution 4.0 International License (CCBY-4.0). View this license's legal deed at http://creativecommons.org/licenses/by/4.0 and legal code at http://creativecommons.org/licenses/by/4.0/legalcode for more information.

REFERENCES

1. Connolly SJ. Evidence-based analysis of amiodarone efficacy and safety. In: Link M, ed. *UpToDate*. Wolters Kluwer; 2025.

2. Murray J, O'Brien S, Mitchell PD. Diffuse alveolar hemorrhage. *Semin Respir Crit Care Med*. Published online November 11, 2025. doi:10.1055/a-2725-7274

3. Giardina EV, Passman R. Amiodarone: clinical uses, administration, and adverse effects. In: Link M, ed. *UpToDate*. Wolters Kluwer; 2025.

4. Borders CW III, Bennett S, Mount C, Claassen SL. A rare case of acute diffuse alveolar hemorrhage following initiation of amiodarone: a case report. *Mil Med*. 2012;177(1):118-120. doi:10.7205/MILMED-D-11-00208

5. Iskandar SB, Abi-Saleh B, Keith RL, Byrd RP Jr, Roy TM. Amiodarone-induced alveolar hemorrhage. *South Med J*. 2006;99(4):383-387. doi:10.1097/01.smj.0000208971.43461.bb

6. SA SA, Triantafillidou C, Kolilekas L, Markoulaki D, Manali ED. Amiodarone: review of pulmonary effects and toxicity. *Drug Saf*. 2010;33(7):539-558. doi:10.2165/11532320-000000000-00000

7. Grippi MA, Antin-Ozerkis DE, Dela Cruz CS, Kotloff RM, Pack AI. *Fishman's Pulmonary Diseases and Disorders*. McGraw-Hill Education; 2023.

8. Israël-Biet D, Venet A, Caubarrère I, et al. Bronchoalveolar lavage in amiodarone pneumonitis. Cellular abnormalities and their relevance to pathogenesis. *Chest*. 1987;91(2):155-158.

9. Martin WJ, Rosenow EC. Amiodarone pulmonary toxicity. Recognition and pathogenesis (Part 2). *Chest*. 1988;93(6):1242-1248.

10. Ageno W, Gallus AS, Wittkowsky A, Crowther M, Hylek EM, Palareti G. Oral anticoagulant therapy: Antithrombotic Therapy and Prevention of Thrombosis, 9th ed: American College of Chest Physicians evidence-based clinical practice guidelines. *Chest*. 2012;141(2 suppl):e44S-e88S. doi:10.1378/chest.11-2292

11. Argyriou M, Hountis P, Antonopoulos N, Mathioudaki M. Acute fatal post-CABG low dose amiodarone lung toxicity. *Asian Cardiovasc Thorac Ann*. 2007;15(6):e66-e68. doi:10.1177/021849230701500626

12. Fernando HC, Jaklitsch MT, Walsh GL, et al. The Society of Thoracic Surgeons practice guideline on the prophylaxis and management of atrial fibrillation associated with general thoracic surgery: executive summary. *Ann Thorac Surg*. 2011;92(3):1144-1152. doi:10.1016/j.athoracsur.2011.06.104